

# HOW I EVALUATE WHITE MATTER LESIONS ON BRAIN MRI

WALTER REICHERT, MD

WESTERN NEUROLOGICAL ASSOCIATES

Salt Lake City, Utah



## Case Study:

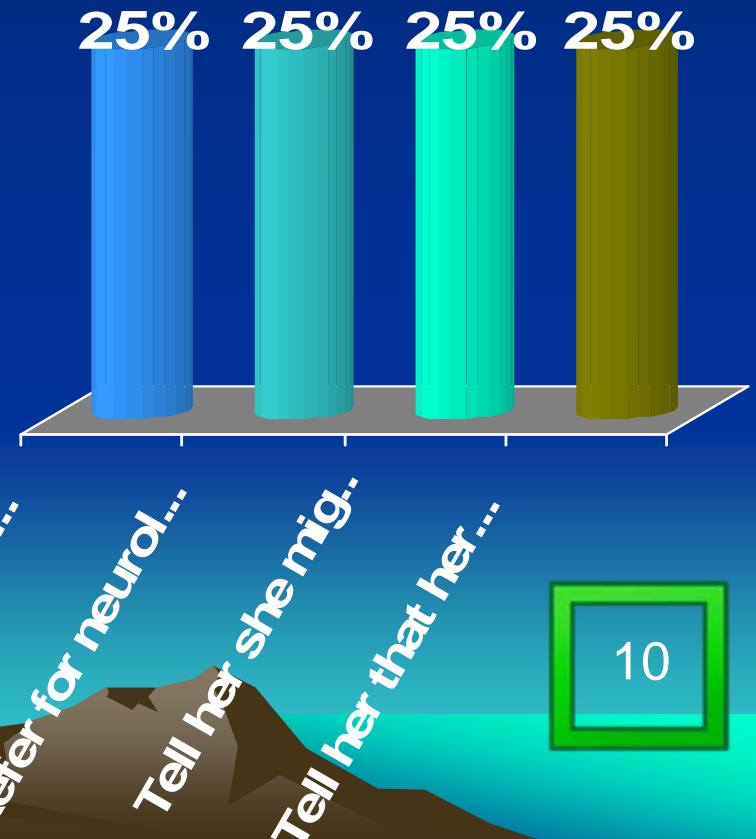
A 35 year old white female is seen for intermittent vertigo. Her past history is significant for migraine with aura.

Her neurological examination is normal.

An MRI of the brain shows “ a few non-enhancing foci of increased signal intensity.

At this time you would:

1. Refer for ENT consultation
2. Refer for neurological consultation
3. Tell her she might have multiple sclerosis
4. Tell her that her MRI scan is normal



# An approach to evaluating white matter lesions

1. The patients history, including why the imaging was ordered
2. The patients age
3. Co-morbid conditions
4. Physical examination findings
5. I review for myself the MRI
6. Discuss the diagnostic possibilities and further evaluations with the patient
7. It's not easy! There are pitfalls and zebras out there.

